

**Syllabus :** Skeleton : Movement and Locomotion

- (i) Functions of human skeleton
- (ii) Axial and Appendicular Skeleton
- (iii) Types of joints with reference to their location — immovable joints, slightly movable joints and freely movable (hinge joint, ball and socket joint, gliding joint, pivot joint.)

Most animals are characterized by a definite shape and the capacity for movement of the different parts of the body. These movements also help the animal in locomotion, *i.e.* movement from place to place. These functions are performed by the skeleton and the muscles together.

### 12.1 FUNCTIONS OF HUMAN SKELETON

The skeleton in our body serves six main purposes :

**1. Support and shape.** The skeleton provides a support or framework to all the soft parts and gives the body and its parts a **definite shape**. Imagine if you did not have small pieces of bones (phalanges) in your fingers, would you be able to hold a pen in your hand ?

An example of shape and support. Just hold your ear, try to fold it and then leave it free. It resumes its shape. Now feel its interior, it is tough but flexible. This is due to the cartilage skeleton inside it, which is giving it support as well as the shape.



**2. Protection.** Several delicate and important organs are well protected by a casing of bones. *For example*, the skull protects the brain, the vertebral column (backbone) protects the spinal cord, the ribs protect the heart and lungs, and so on.

**3. Movement.** Many bones are joined to each other in a manner that one bone can be moved on another. These movements are brought about by muscles which originate on one bone and are inserted on another.

**4. Leverage.** Some bones and joints form levers that increase the speed and distance of movement by a muscle. *For example*, contraction of only a few centimetres by the biceps muscle swings the hand swiftly through an arc of more than a foot (Fig.12.14).

**5. Formation of blood cells.** Certain types of blood cells, including red and white blood cells are formed in the tissue of the central hollow space or the marrow of some of the long bones.

**6.** The bones are a **storehouse of calcium and phosphorus** for the rest of the body.

### CONSTITUENTS OF SKELETON

Our skeleton consists of bones, cartilages and ligaments.

- **Bones** comprise the hard framework of the body.
- **Cartilages** are the supporting and connecting structures. *For example*, the cartilage supporting the projecting external ears and the tip of the nose.
- **Ligaments** bind the bones together.

### 12.2 BONE

Bone is the chief component of our skeleton. It consists of organic and inorganic material. The inorganic part constitutes nearly two-thirds of the entire bone substance, and includes mainly the compounds of calcium and phosphorus. If a bone is placed in weak hydrochloric acid, the mineral part is removed from it (gets dissolved) and the remaining organic framework is left behind. Such a bone is called **decalcified** (calcium removed) bone and it is soft and flexible which can even be tied into a knot.

## BONE

### Long bones

Consist of a shaft with a knob at each end. Shaft is thick - walled, tubular, filled with yellow marrow, ends are spongy e.g., bones of arms, legs, and chest (ribs)

### Short bones

Box like, spongy bone, show little movement, e.g. ankle, wrist.

### Flat bones

Composed of two or more parallel plates of compact bone enclosing spongy bone e.g. shoulder blade, skull, sternum

### Irregular bones

Complex shape, vary in amount of bone tissue, compact and spongy e.g. facial bones vertebral bones.

On the other hand, if a bone is strongly heated its organic matter is destroyed (oxidised) and only the mineral part (or ash) will remain. Such a bone turns brittle and quickly breaks. With age, as in old people, the organic part of the bone is reduced and the bones become more fragile taking much time in rejoining after a fracture.

### Classification of bone on the basis of shape.

**Shapewise** bones are classified into : **long**, **short**, or **flat** and **irregular** bones, as given in the above scheme.

The **structure** of a typical long bone (e.g. thigh bone) (Fig. 12.1). It is a highly calcified (mineralised), hard and rigid connective tissue. It is very strong and can withstand severe stresses. It consists of bone cells (Osteocytes) arranged in the form of concentric rings (Fig. 3.10) embedded in a ground matrix in which collagen fibres and mineral salts (calcium and phosphorus) are deposited.

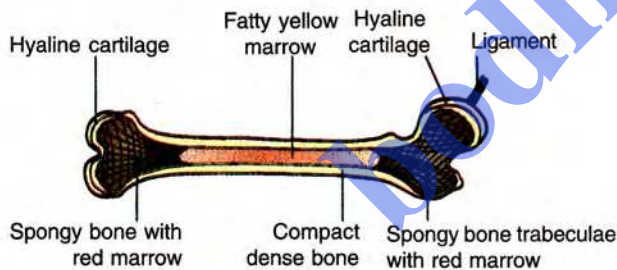


Fig. 12.1 Structure of a long bone.

The **external surface** of the bone is covered by a membrane called periosteum which consists of outer fibrous and inner cellular layers and richly supplied with blood vessels. A long bone has a hollow cavity in the middle which is filled with bone marrow. Marrow is of two types (i) **yellow marrow**, made up of adipose tissue and blood vessels which give rise to white blood cells (ii) **red marrow**, which is present at the ends and produces red blood cells.



### PROGRESS CHECK

#### Fill in the blanks:

- Our skeleton consists of bones, \_\_\_\_\_, and \_\_\_\_\_.
- \_\_\_\_\_ is the chief component of our skeleton.
- Shapewise the bones can be classified as \_\_\_\_\_, \_\_\_\_\_, and \_\_\_\_\_.
- The central hollow part of the long bones is known as \_\_\_\_\_.
- A bone becomes soft and flexible when placed in dilute \_\_\_\_\_.

### 12.3 THE HUMAN SKELETON (Fig. 12.2)

The human skeleton altogether consists of 206 bones including three very tiny bones in each ear. Table 14.1 (p. 126) gives a detailed regionwise break-up of the total number of bones in the human skeleton. The skeleton has two main divisions : the **axial skeleton** which includes the basic central framework of the body and the **appendicular skeleton** which includes the bones of the limbs and girdles.

#### 12.3.1 AXIAL SKELETON

The axial skeleton consists of the skull, the vertebral column, the ribs and the sternum.

**A. SKULL** is the skeleton of the head. It contains two parts. The upper top part the **cranium** (or the brain-box) is made of **eight bones** which are so joined to each other that they are permanently fixed. The other part of the skull forms the face which contains a total of fourteen bones. The upper and lower jaws are also formed by some of these bones. The back part of the cranium contains a large hole, the **foramen magnum**, through which the spinal cord after emerging from the brain continues behind into the backbone.

**B. VERTEBRAL COLUMN** (Fig. 12.3A). The vertebral or spinal column is popularly called the backbone. It is composed of a total of 33 ring-like bones called **vertebrae**. These are divided into five

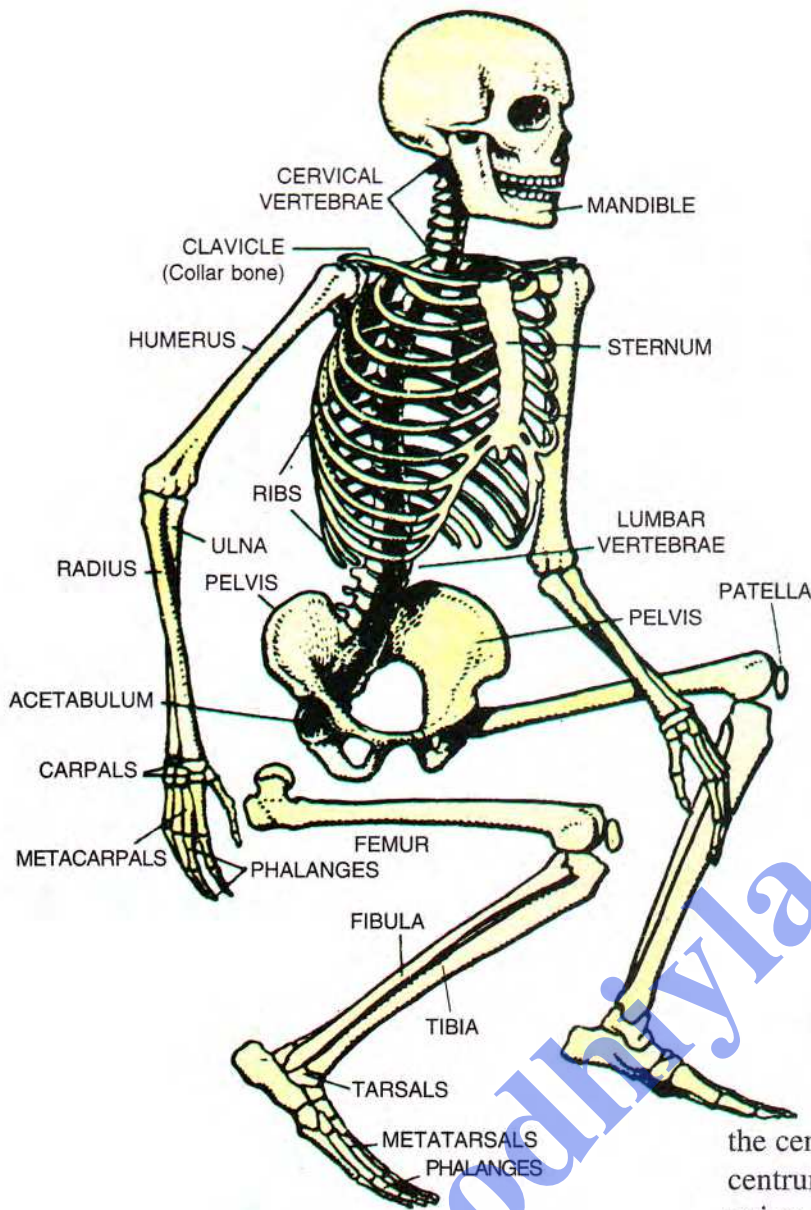


Fig. 12.2 The human skeleton.

groups according to the regions they occupy. The neck region has seven **cervical vertebrae**, then there are twelve **thoracic**, five **lumbar**, one **sacrum** (fused five), and one **coccyx** (fused four).

Vertebral column is curved to maintain balance of body in an erect position. The curve absorbs pressure and shock while walking, running and protects the column from breaking.

**Structure of vertebra.** Each vertebra is a somewhat ring-like structure (Fig. 12.3D). Its lower part (front in actual position in the human body) is formed of a solid cylinder of bone called **centrum** (or the **body of vertebra**). The two opposite ends of

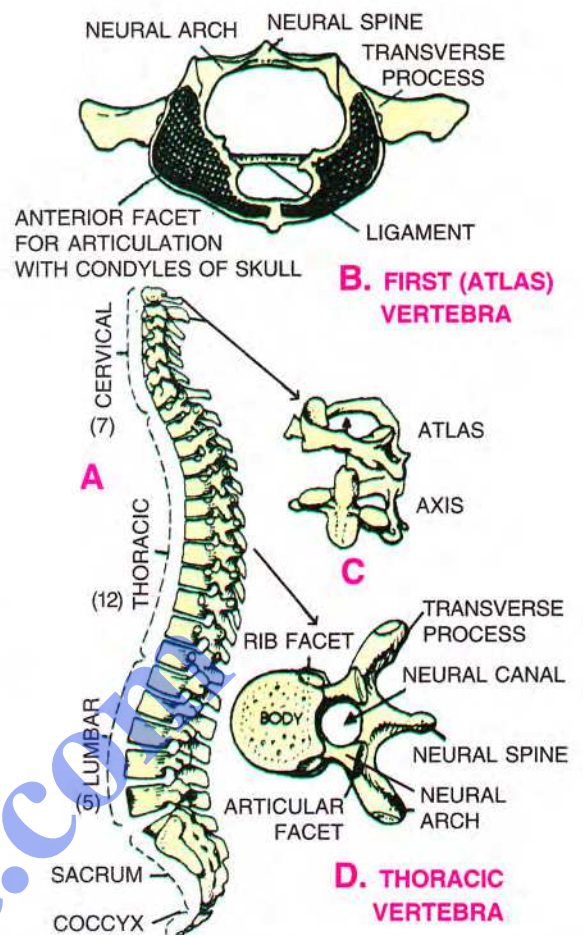


Fig. 12.3 A—Side view of human vertebral column, showing its curves and details of individual vertebrae; B—Anterior (front) view of first (atlas) vertebra; C—Atlas and axis vertebrae (side view); D—Thoracic vertebra.

the centrum are flat. On the dorsal (back) side of the centrum is a canal (**neural canal**) formed by the union of two **neural arches** arising from the sides of the centrum. In natural position the spinal cord runs through this neural canal. **Neural spine** is a flat longitudinal ridge projecting upward from the meeting point of the two neural arches. **Transverse processes** are thick sideward projections from the neural arches. The neural arches also bear **articular facets** (one in front and one behind on either side) which help in joining the two vertebrae one behind the other. A pad of cartilage **intervertebral disc** or **gristle** forms a kind of cushion between two vertebrae.

**Neck/cervical vertebrae.** The first cervical vertebra is called the **atlas** (Fig. 12.3B, C). The second vertebra is the **axis**. The remaining five neck vertebrae do not have any special names.

**Thoracic vertebrae** (Fig. 12.3A) have long neural spines which are directed backward. Each of their transverse processes bears on its extremity a **facet** for articulation with the tubercle of the rib.

**Lumbar vertebrae** have well-developed neural spines and transverse processes which serve for the attachment of powerful back muscles.

**Sacrum** is a large bone formed by the fusion of five vertebrae. To it are articulated the hip bones on either side.

**Coccyx** is the last part of the backbone. It is made up of four fused vertebrae which represent the rudimentary tail of the human body. Sometimes as a freak of nature, babies are born with a small tail, which the doctors usually remove (see photograph at the end of Review Questions, page 130).

**C. RIBS.** There are **twelve pairs** of ribs which along with the thoracic vertebrae and the breast-bone constitute the **bony cage** or **rib cage**. The first seven pairs of ribs **true ribs** are attached in front to the sternum (breast-bone) with the help of hyaline cartilage. The 8th, 9th and 10th pairs of ribs do not articulate directly with the sternum but join the seventh rib with the help of hyaline cartilage. The last two, 11th and 12th pairs of ribs, are not attached to the sternum and are, therefore, known as **floating ribs** (Fig. 12.4).

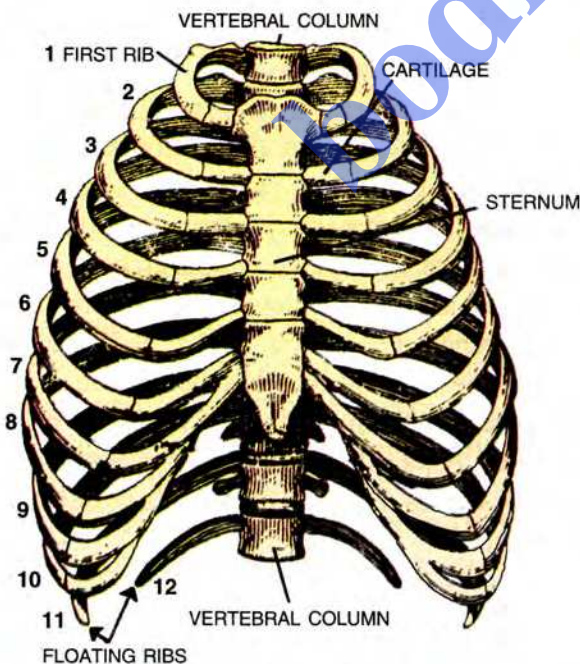


Fig. 12.4 The bony thorax (seen from the front)

**D. STERNUM.** The *sternum* (breast-bone) is a long flat bone lying in the middle of the front part of the chest.

### 12.3.2 APPENDICULAR SKELETON (Bones of limbs and girdles)

**A. BONES OF THE LIMBS.** Bones of the forelimbs and the hind-limbs largely correspond to each other. The forelimbs consists of a single long bone **humerus** in the upper arm, two long bones in the lower arm, the **radius** on the side of the thumb and the **ulna**. Eight **carpals** or wrist bones in the wrist, five **metacarpals** in the palm and fourteen **phalanges** (2 in the thumb and 3 each in the remaining four fingers).

The hind-limb consists of a long bone **femur** or **thigh bone** (longest and strongest bone) in the thigh, two long bones the inner **tibia** and the outer **fibula** in the shank, seven **tarsal** bones in the ankle, five long **metatarsal** bones in the middle of the foot and fourteen **phalanges** just as those in the fingers, *i.e.* 2 in greater toe and three each in the other four toes. The hind-limbs have an additional bone called **patella** (or the *knee-cap*) which is joined to the lower end of the femur. Knee-cap is a bone developed from a tendon.

**B. GIRDLES.** Girdles are the parts of skeleton which help to articulate the limb bones to the main (axial) skeleton. There are two girdles—shoulder girdle and the hip girdle. The **shoulder pectoral girdle** (Fig. 12.5) consists of two flat triangular **scapula** (shoulder-blade) which lie dorsally on the upper ribs on either side of the vertebral column in the thorax region. Its outer apex bears a large somewhat cup-shaped **glenoid cavity** into which fits the rounded upper head of the humerus, and close to this joint the shoulder-blade has a small raised part to which a long and curved **collar-bone (clavicle)** is attached. The other end of the collar-bone is joined to the uppermost part of the breast-bone/sternum.

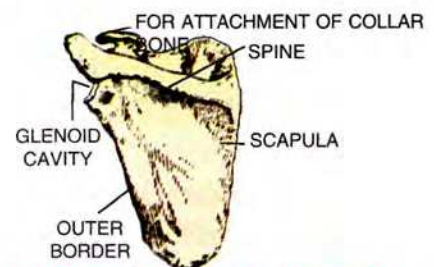


Fig. 12.5 Pectoral (shoulder) girdle (left) as viewed from the back side)

The **hip pelvic girdle** (Figs. 12.2, 12.6) is a large trough-shaped part formed by two hip bones that are joined medially to the sacrum. Each hip bone is made up of three bones the ilium, ischium and pubis. On each side it bears a large cup-shaped articular cavity (**acetabulum**) into which fits the large round head of the thigh-bone. The hip girdle not only gives support to the skeleton of the hind-limbs, but also protects and supports the abdominal organs.

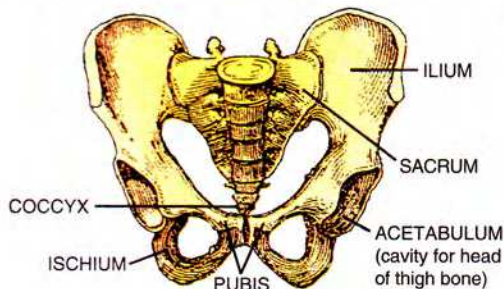


Fig. 12.6 The pelvis (seen from the front)

**Difference between male and female skeleton.**

Male skeleton is generally larger and heavier. In the female the pelvis or hip bone is wider and trough-shaped to adapt for accommodating the foetus in the uterus during pregnancy.

Table 12.1 Regionwise classification of bones and their number in humans.

Region of skeleton	Number of bones
<b>1. Axial skeleton</b>	
— Skull (including ear bones)	29
— Vertebrae	33
— Ribs	24 (12 pairs)
<b>2. Appendicular skeleton</b>	
— Shoulder girdle (Clavicles 2 + Scapula 2)	4
— Arms	60
— Pelvic girdle	2
— Legs	60
— Patella	1
<b>Total 213</b>	

**12.4 JOINTS**

The point at which two separate bones meet is called a **joint**. There are three major categories of joints in our body :- Immovable, partially movable and freely movable.

**1. IMMOVABLE JOINTS.** In this type of joint no movement is possible between the two bones. The

sutures between the bones of the skull box are examples of immovable joint (Fig. 12.7).

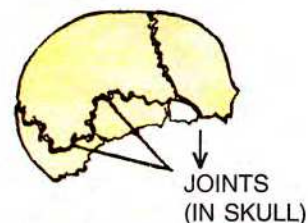


Fig. 12.7 Immovable joint

**2. PARTIALLY MOVABLE JOINTS.**

Here only very little (partial) movement occurs between the two bones. *Examples* : the joint between a rib and the breast-bone or between the vertebrae.

**3. FREELY MOVABLE JOINTS.** In this type varying degrees of movement are possible between the two bones forming the joint. The four major types of movable joints are as follows:

(a) **Gliding joint** [Fig. 12.8(a)]. It occurs between the **bones of the wrist** and also between the **bones of the ankle** as well as **between vertebrae**.

(b) **Pivot joint** [Fig. 12.8(b)]. Here one bone is rotated over a pivot-like end of another bone. *For example*, the skull is rotated on the upper end of the axis vertebra.

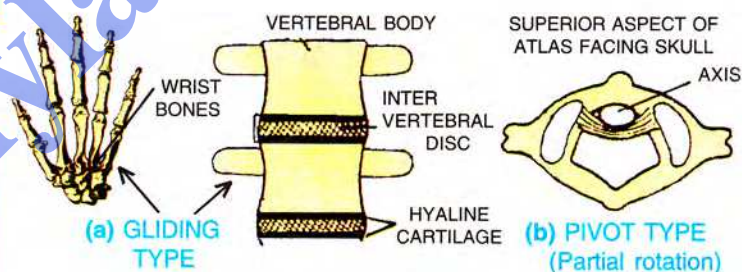


Fig. 12.8 Partially movable joints

(c) **Hinge joint** [Fig. 12.9(a)]. This joint moves like a hinge in one plane only just like the hinge of a door. *Example* : elbow joint between humerus and ulna, joints between the bones of fingers and the toes, and less perfectly the knee joint. The hinge joints usually give sufficient power.

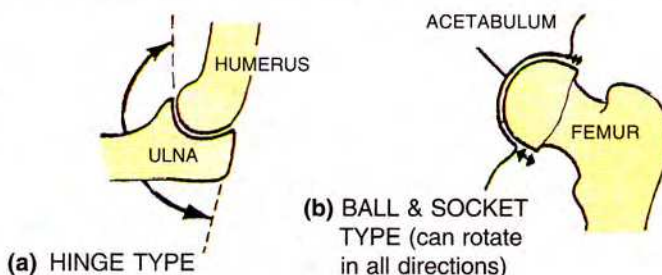


Fig. 12.9 Movable joints

(d) **Ball and socket joint** [Fig. 12.9(b)]. Here one end of a bone which is rounded and ball-like, fits into a cup-like depression of another bone. This joint provides movement in any direction. Two best examples are the shoulder joint and the hip joint. In the shoulder joint the head of humerus fits into a socket (glenoid cavity) of the shoulder girdle, and in the hip joint the large ball-like head of femur fits into the deep socket (acetabulum) of the hip girdle.

**SYNOVIAL JOINTS.** The freely movable joints stated above, like the shoulder joint, the knee joint are also called synovial joints, They allow considerable degree of movement. These joints have two special requirements—firstly, they should be held firmly in position and secondly, the surfaces coming into contact should be well lubricated to remove friction. The lubricating fluid wherever it occurs, is called the **synovial fluid** and hence the name synovial joint (Fig. 12.10). The knee joint (Fig. 12.11), for example, is a synovial joint. It is

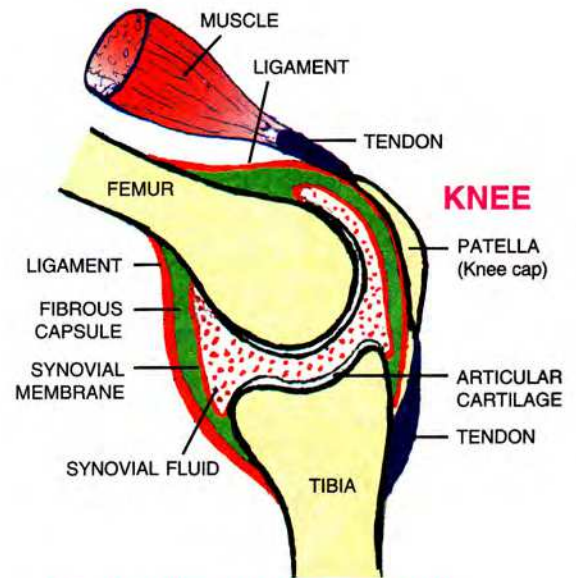


Fig. 12.11 Knee joint (diagrammatic)

held in position by strong **ligaments** and is well protected by an outer **fibrous capsule**. The ligaments prevent dislocation in normal movement. The **synovial fluid** is contained in a “sac” formed of very thin **synovial membrane** and this sac serves as a cushion between the bones.

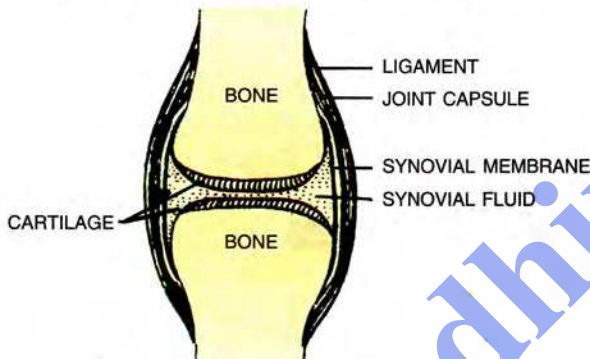


Fig. 12.10 Section of a typical movable synovial joint (diagrammatic)

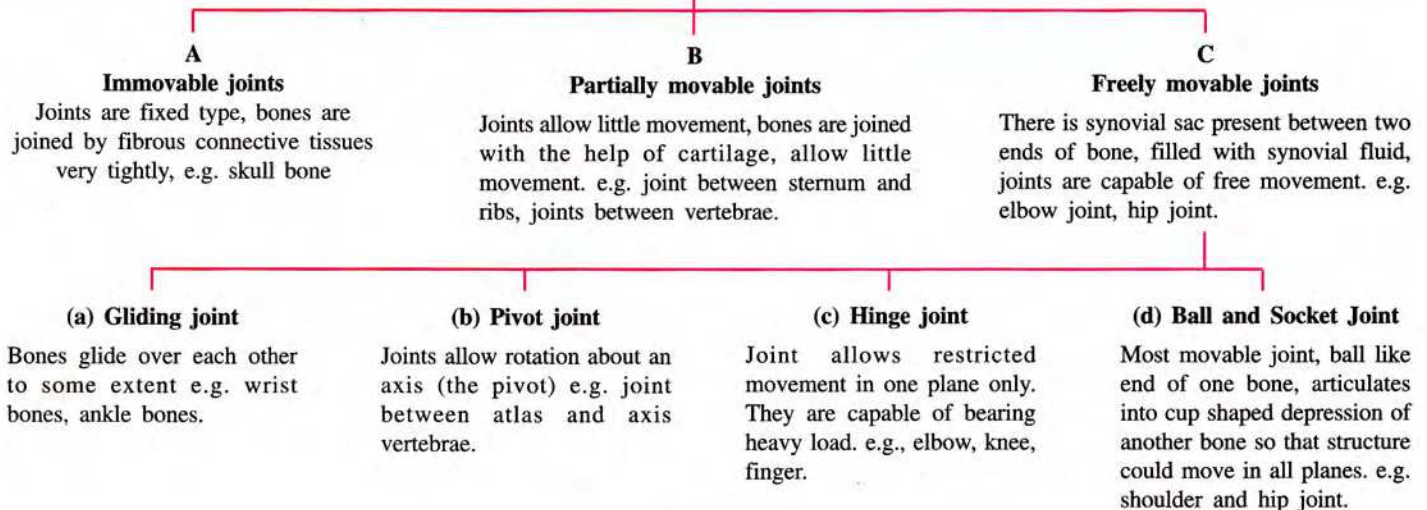
**PROGRESS CHECK**

Mention if the following statements are true (T) or false (F)

- (i) Humerus of the upper arm is the longest bone. T/F
- (ii) Axial skeleton includes shoulder and hip girdles. T/F
- (iii) There are 10 vertebrae in the neck T/F
- (iv) There are three kinds of ribs - true, false and floating T/F
- (v) The shoulder girdle is large and trough-shaped T/F

**CLASSIFICATION OF JOINTS**

**JOINT**



## 12.5 MUSCLES

- The muscles in the body provide the means of all movements.
- They cover the skeletal framework and also give contour (shape) to the body.
- Muscles help to maintain body posture while sitting, standing or walking.

Most muscles are long bundles of contractile tissue. Each muscle usually has two ends—a **fixed end** where the muscle originates and a **movable end** which pulls some other part. This movable end is drawn out to form a tough structure the **tendon** which is attached to the bone (Fig. 12.12). When stimulated by a nerve the muscle contracts to become shorter and thicker and thus it pulls the bone at the movable end (Fig 12.12 & 12.13). Muscles can only contract and relax, they cannot lengthen.

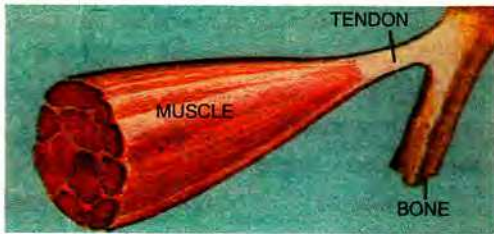


Fig. 12.12 Tendons are composed of tough collagen fibres which withstand the strains involved

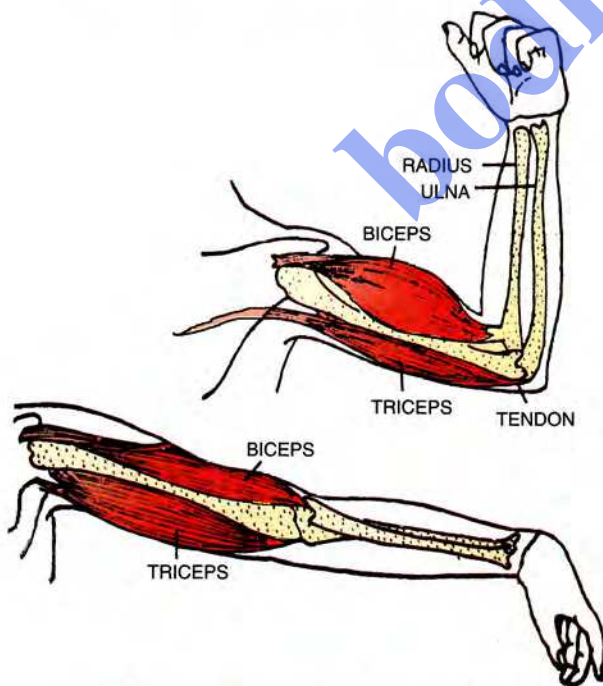


Fig. 12.13 Antagonistic muscles of arm.

**Antagonistic muscles.** A structure which has been moved by a muscle cannot return to its original position without the action of another muscle. Such muscles causing opposing movements are called **antagonistic muscles**. For example, the **biceps** (flexor) muscle of the upper arm flexes, *i.e.* bends the lower arm over the upper arm. Straightening (extension) of the lower arm is brought about by the **triceps** (extensor) muscle (Fig. 12.13). Therefore, these two muscles are antagonistic.

### Kind of muscles – Voluntary, involuntary and cardiac

There are about 400 muscles in our body making up nearly one-half of the body weight. These muscles fall into two categories—**voluntary muscles** which are under control of our will and **involuntary muscles** which are not controlled by our will. Some muscles, like those of the eyelids and diaphragm are both voluntary as well as involuntary. **Cardiac muscles** (Chapter 3, p 25, 26) make up the walls of the heart. They are capable of rapid movements and do not tire easily.

**Coordination of muscles.** Most actions in our body like standing, walking, running, playing tennis, *etc.*, require combined action of several muscles. To a great extent the muscles have to be co-ordinated for a particular kind of movement.

## 14.6 LEVER MECHANISMS

Movements of different parts of the body are usually made easier due to **lever actions** in the skeleton (Fig. 12.14 & 12.15). The lever of the **first order** where the **power (P)** and the **weight (W)** act

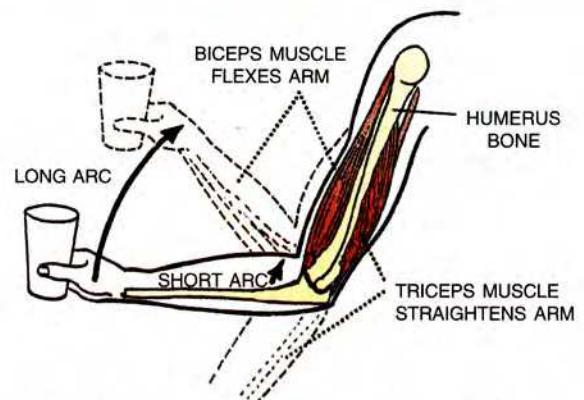


Fig. 12.14 Diagram of the mechanics of flexion and extension of the elbow joint

with the **fulcrum (F)** in between is represented by extension of the arm at the elbow by the action of triceps muscle (A) and resting of skull on first and second neck vertebrae. The lever of the **second order** where the fulcrum is at one end of the lever and power at the other end with the weight in between is represented by the gastrocnemius muscle raising weight of the body on the toes (B). The lever of the **third order** where the fulcrum is at one end and the weight at the other with the power in between is represented by the biceps muscle flexing the arm (C).

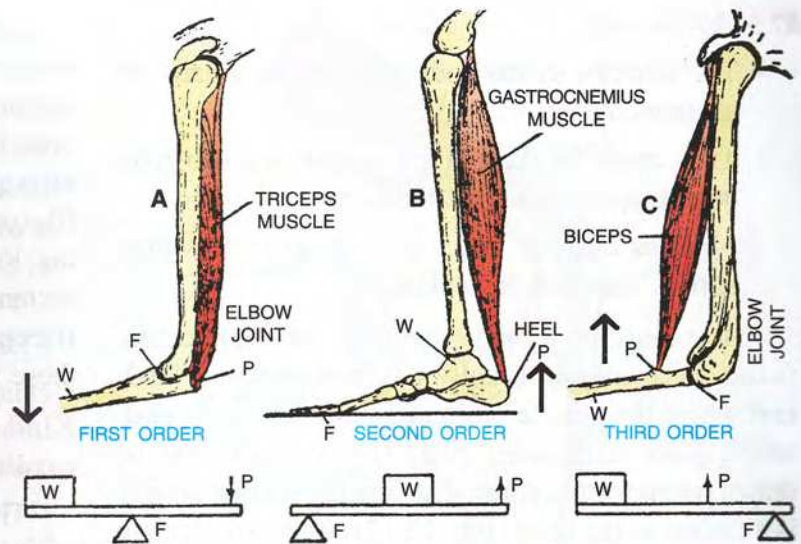


Fig. 12.15 Simple levers in human skeleton. A. Elbow (extension of arm); B. Toes and heel (lifting up of heel); C. Elbow (flexion of arm) (P = power, F = fulcrum, W = weight)

### DO YOU KNOW ?

- The **longest bone** in our body is the thigh bone (femur).
- The **smallest bones** in our body are the three tiny bones (malleus, incus and stapes) in the ear joined to the inner side of the ear drum in the form of a chain.
- The **nails and the teeth**, though hard, are not bones.
- Most muscles are attached to bones, but some are not. *For example*, the muscles which move our eyelids or the muscles that push the food along the food canal are not attached to bones.
- Some muscles in our body are **vestigial (non functional)** such as the muscles of the projecting ears. Other mammals like the cow or horse can move their ears. Some persons also, with some effort, can learn to move their ears slightly.



### PROGRESS CHECK

1. Mention if the following statements are **true (T)** or **false (F)**.
  - (i) The flexor and extensor muscles of the arm are antagonistic muscles T/F
  - (ii) Muscles can contract as well as elongate T/F
  - (iii) Muscles are attached to bones by ligaments T/F
  - (iv) Cardiac muscle is a voluntary muscle T/F
  - (v) Bending of arm on elbow is an example of first order of lever mechanism T/F

2. Match the bones (Column I) with the kind of joint (Column II)

Column I (Bones)	Column II (Joint)
(i) Humerus and shoulder girdle	(a) Partially movable
(ii) Two adjacent vertebrae	(b) Gliding
(iii) Skull and upper end of the backbone	(c) Immovable
(iv) Bones of brain box	(d) Ball and socket
(v) Rib and breast bone	(e) Pivot

### POINTS TO REMEMBER

- *Skeleton performs four primary functions : support, protection, movement and leverage.*
- *Bones are storehouse of calcium and phosphorus and the hollow long bones produce blood cells.*
- *The human skeleton consists of axial skeleton (backbone and ribs) and appendicular skeleton (bones of limbs and girdles)*
- *The joints between two bones may be immovable, partially movable and freely movable.*
- *Movable joints are of four kinds — gliding joint, hinge joint, pivot joint and ball and socket joint.*
- *Most movable joints have a lubricating synovial fluid between the two bones*
- *Antagonistic muscles bring about opposite movements of the part concerned.*
- *Human skeleton provides examples of all the three orders of lever.*



## REVIEW QUESTIONS

### A. MULTIPLE CHOICE TYPE

- Your external ear (pinna) is supported by
  - Bone
  - Cartilage
  - Tendon
  - Capsule
- The type of joint found at shoulder is also found at
  - Elbow
  - Knee
  - Ankle
  - Hip
- Which one of the following categories of vertebrae are correctly numbered
  - Cervical — 7
  - Thoracic — 10
  - Lumbar — 4
  - Sacral — 4
- Human skeleton altogether contains 213 bones. Which of these are the 6 bones?
  - Neck vertebrae
  - Ear ossicles
  - Carpals
  - Metacarpals

### B. VERY SHORT ANSWER TYPE

- Name the parts of the skeleton where the following are located : transverse process, glenoid cavity, shoulder-blade, acetabulum.
- Name any two parts of your body where the supporting skeleton is made of cartilage instead of bone.

### C. SHORT ANSWER TYPE

- What is the **difference** between a true rib and a floating rib ?
- Do the muscles pull the structures, or push them ? **Explain** briefly.
- Just as the humerus corresponds to femur, what bones correspond to tarsals, metacarpals, ulna and radius respectively ?
- What are **antagonistic** muscles ? Give one example.

- Some people in old age complain of stiff joints. What do you think could be a possible reason for it?

### D. LONG ANSWER TYPE

- What are the **uses of the skeleton** in our body?
- Name the **different types of joints** ? Give one example of each type.
- What is the **difference** between ligament and tendon ? What are their functions ?
- What are bones made of ? Are the bones living or non-living ? Give reason.
- Given below is a diagram of human skeleton. Name the bones numbered 1-11.

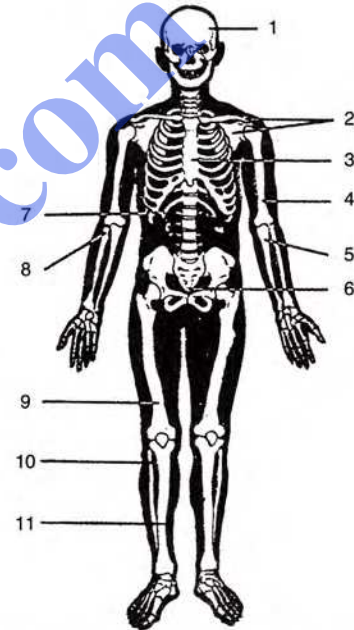


Fig. 12.16 The human skeleton.



### CAN YOU MAKE OUT THE PECULIARITY IN THE BABY ?

#### A TAILED BABY

Such cases are found but rarely. The doctors in maternity homes generally remove this kind of a tail surgically.

A rudimentary tail, the coccyx, which is the last part of the backbone is found in all of us, but it is very small and never projects out.